

CLINICAL PRACTICE

Diverticulitis

Danny O. Jacobs, M.D., M.P.H.

This Journal feature begins with a case vignette highlighting a common clinical problem. Evidence supporting various strategies is then presented, followed by a review of formal guidelines, when they exist. The article ends with the author's clinical recommendations.

A previously healthy 45-year-old man presents with severe lower abdominal pain on the left side, which started 36 hours earlier. He has noticed mild, periodic discomfort in this region before but has not sought medical treatment. He reports nausea, anorexia, and vomiting associated with any oral intake. On physical examination, his temperature is 38.5°C and his heart rate is 110 beats per minute. He has abdominal tenderness on the left side without peritoneal signs. How should his case be managed?

THE CLINICAL PROBLEM

Colonic diverticular disease is rare in developing nations but common in Western and industrialized societies, accounting for approximately 130,000 hospitalizations yearly in the United States.¹ The prevalence of diverticulosis is similar in men and women and increases with age, ranging from approximately 10% in adults younger than 40 years of age to 50 to 70% among those 80 years of age or older^{2,3}; 80% of patients who present with diverticulitis are 50 or older.⁴ The disease affects the sigmoid and descending colon (where diverticula are usually found) in more than 90% of patients⁵; this review focuses on diverticulitis at these sites.

The terms “diverticulosis” and “diverticular disease” are used to describe the presence of uninflamed diverticula. Diverticular disease of the colon is also a relatively common cause of acute lower gastrointestinal bleeding and is the diagnosis in 23% of patients who present with acute symptoms.⁶ The term “diverticulitis” indicates the inflammation of a diverticulum or diverticula, which is commonly accompanied by gross or microscopical perforation.

Whereas the cause of colonic diverticular disease has not yet been conclusively established, epidemiologic studies have demonstrated associations between diverticulosis and diets that are low in dietary fiber and high in refined carbohydrates.^{7,8} Low intake of dietary fiber results in less bulky stools that retain less water and may alter gastrointestinal transit time; these factors can increase intracolonic pressure and make evacuation of the colonic contents more difficult.² Other factors that have been associated with an increased risk of diverticular disease include physical inactivity, constipation, obesity, smoking, and treatment with nonsteroidal antiinflammatory drugs.⁵

Increased intracolonic pressures have been recorded in patients with diverticulosis.^{9,10} Colonic pseudodiverticula, outpouchings consisting of only mucosa and submucosa, may develop in response to increased intraluminal pressure and protrude at areas of potential weakness, such as where the bowel wall is penetrated by its vasculature¹¹ (Fig. 1).

From the Department of Surgery, Duke University School of Medicine, and Duke University Hospital, Durham, NC. Address reprint requests to Dr. Jacobs at the Department of Surgery, Duke University Medical Center, DUMC Box 3704, Durham, NC 27710.

N Engl J Med 2007;357:2057-66.

Copyright © 2007 Massachusetts Medical Society.

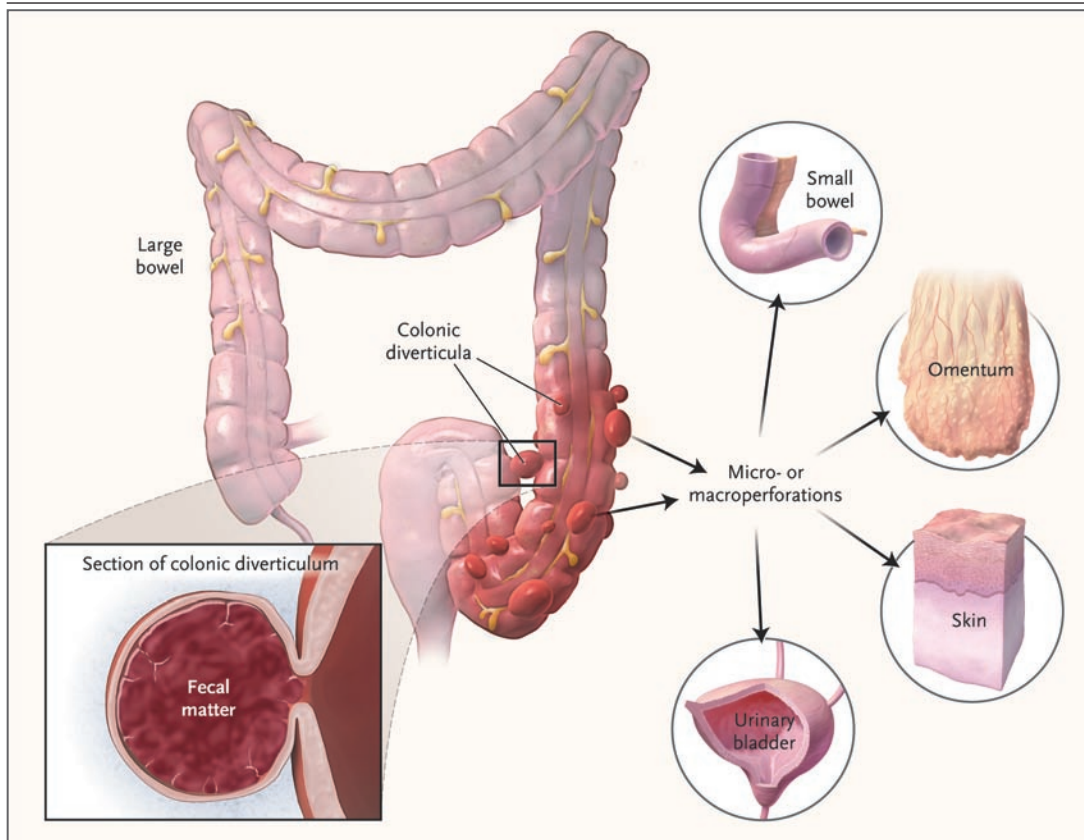


Figure 1. Colonic Diverticula.

Colonic diverticula have narrow necks that can be easily obstructed by fecal matter. Obstruction of the neck sets a cascade of events in motion that may include distention of the sac, bacterial overgrowth, vascular compromise, and perforation. When perforations occur, they are often contiguous with other tissues or organs, such as the omentum, mesocolon, bladder, or small bowel. Some perforations are localized and contained, whereas others may invade the skin or erode into adjacent viscera, causing fistulas. Fistulization most frequently involves the colon and bladder (in up to 65% of cases), although the bladder is a less frequent site in women if the uterus is present.

The pathogenesis of diverticulitis is uncertain. However, stasis or obstruction in the narrow-necked pseudodiverticulum may lead to bacterial overgrowth and local tissue ischemia, findings that are similar to those described in appendicitis. Anaerobes (including bacteroides, peptostreptococcus, clostridium, and fusobacterium species) are the most commonly isolated organisms. Gram-negative aerobes, especially *Escherichia coli*, and facultative gram-positive bacteria, such as streptococci, are often cultured as well.¹²

“Complicated” diverticulitis is present when there is an abscess or phlegmon, fistula formation, stricture disease, bowel obstruction, or peritonitis. Generalized peritonitis may result from

rupture of a peridiverticular abscess or from free rupture of an uninflamed diverticulum. Only 1 to 2% of patients who present for urgent evaluation have free perforation. High-grade colonic obstruction, though relatively uncommon, may result from abscess formation or edema or from stricture formation after recurrent attacks of diverticulitis.¹³ Small-bowel obstruction may occur somewhat more frequently, especially in the presence of a large peridiverticular abscess.

The consequences of diverticulitis may be more severe in immunocompromised patients, including those who have undergone organ transplantation, have human immunodeficiency virus infection, or are taking corticosteroids. These patients

may have atypical signs and symptoms, are more likely to have free perforation, are less likely to have a response to conservative management, and have higher postoperative risks of complications and death than immunocompetent patients.^{2,14}

DIAGNOSIS AND EVALUATION

The clinical manifestations of acute colonic diverticulitis vary with the extent of the disease process. In classic cases, patients report obstipation and abdominal pain that localizes to the left lower quadrant. An abdominal or perirectal fullness, or “mass effect,” may be apparent. Stool guaiac testing may be trace-positive. A low-grade fever is common, as is leukocytosis.

Alternative diagnoses for lower abdominal pain must be considered. Sigmoid diverticulitis may mimic acute appendicitis if the colon is redundant or otherwise configured such that the inflamed portion resides in the suprapubic region of the right lower quadrant. Inflammatory bowel disease (especially Crohn’s disease), pelvic inflammatory disease, tubal pregnancy, cystitis, advanced colonic cancer, and infectious colitis may also have presentations similar to that of diverticulitis.

Patients with free perforation have peritoneal irritation, including marked abdominal tenderness that begins suddenly and spreads rapidly to involve the entire abdomen with guarding and involuntary rigidity. Peritonitis is an indication for emergency surgical exploration.

STAGING

The severity of diverticulitis is often graded with the use of Hinchey’s criteria (Fig. 2), although this classification system does not take into account the effects of coexisting conditions on disease severity or outcome. The risk of death is less than 5% for most patients with stage 1 or 2 diverticulitis, approximately 13% for those with stage 3, and 43% for those with stage 4.¹⁵

IMAGING AND ENDOSCOPY

Computed tomography (CT) is recommended as the initial radiologic examination (Fig. 3). It has high sensitivity (approximately 93 to 97%) and specificity approaching 100% for the diagnosis,^{16,17} and it allows delineation of the extent of the disease process.^{18,19} In occasional cases, when

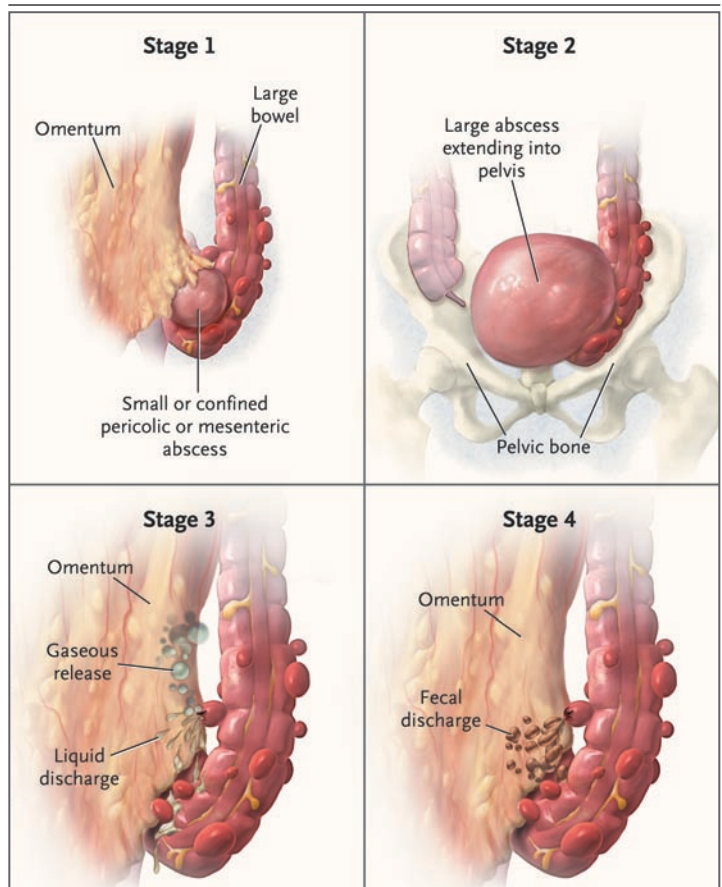


Figure 2. Hinchey Classification Scheme.

Patients with stage 1 disease have small, confined pericolic or mesenteric abscesses, whereas those with stage 2 disease have larger abscesses, often confined to the pelvis. Stage 3 disease, or perforated diverticulitis, is present when a peridiverticular abscess has ruptured and caused purulent peritonitis. Rupture of an uninflamed and unobstructed diverticulum into the free peritoneal cavity with fecal contamination, the so-called free rupture, signifies stage 4 disease and carries the highest risk of an adverse outcome.

it is difficult to distinguish between diverticulitis and carcinoma, limited contrast studies of the descending colon and rectum with the use of water-soluble contrast material may be helpful. The presence of diverticula, inflammation of the pericolic fat or other tissues, bowel-wall thickness of more than 4 mm, or a peridiverticular abscess strongly suggests diverticulitis.² CT may also reveal other disease processes accounting for lower abdominal pain, such as appendicitis, tubo-ovarian abscess, or Crohn’s disease.

Colonoscopy and sigmoidoscopy are typically

Figure 3. CT Scans of the Colon in Four Patients with Diverticulitis of Varying Severity.

Panel A shows diverticula (arrow) and evidence of inflammation and wall thickening (arrowhead), findings that are consistent with Hinchey stage 1 disease. Panel B shows a peridiverticular abscess (circled), a finding consistent with stage 2 disease. Panel C shows a drain within a large, confined diverticular abscess (circled) that communicated with the colon, which is consistent with stage 3 disease. Panel D shows evidence of free perforation (arrows) near thickened descending colon, a finding that is consistent with stage 3 or 4 disease. Images courtesy of Dr. Erik Paulson, Department of Radiology, Duke University Medical Center.

avoided when acute diverticulitis is suspected because of the risk of perforation or other exacerbation of the disease process. Expert opinion is in favor of performing these tests when the acute process has resolved, usually after approximately 6 weeks, to rule out the presence of other diseases, such as cancer and inflammatory bowel disease.

HOSPITALIZATION

The decision to hospitalize a patient for diverticulitis depends on the patient's clinical status. For most patients (i.e., immunocompetent patients who have a mild attack and can tolerate oral intake), outpatient therapy is reasonable. This involves 7 to 10 days of oral broad-spectrum antimicrobial therapy, including coverage against anaerobic microorganisms. A combination of ciprofloxacin and metronidazole is often used, but other regimens are also effective (Table 1). A low-residue liquid diet (i.e., one largely free of indigestible matter) is also commonly recommended, although this approach has not been rigorously studied.

Hospitalization is indicated if the patient is unable to tolerate oral intake or has pain severe enough to require narcotic analgesia, if symptoms fail to improve despite adequate outpatient therapy, or if the patient has complicated diverticulitis. The patient should initially take nothing by mouth. If there is evidence of obstruction or ileus, a nasogastric tube should be inserted. Broad-spectrum intravenous antibiotic coverage is appropriate (Table 1).

If there is no improvement in pain, fever, and leukocytosis within 2 or 3 days, or if serial physical examinations reveal new findings or evidence of worsening, repeat CT imaging is appropriate,

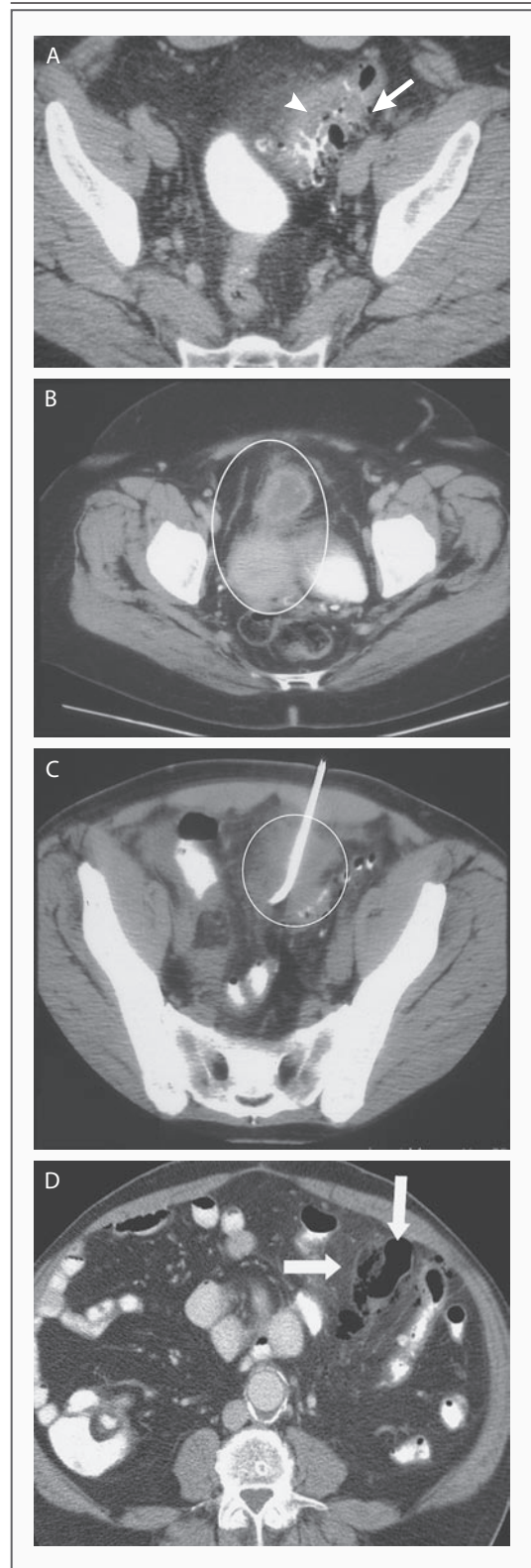


Table 1. Some Regimens Commonly Used to Treat Diverticulitis.*

Drug Regimen	Dosage
Oral regimens for outpatients	
Metronidazole and a quinolone	Metronidazole — 500 mg every 6 to 8 hr
	Quinolone (e.g., ciprofloxacin — 500–750 mg every 12 hr)†
Metronidazole and trimethoprim–sulfamethoxazole	Metronidazole — 500 mg every 6 to 8 hr
	Trimethoprim–sulfamethoxazole — 160 mg trimethoprim and 800 mg sulfamethoxazole every 12 hr†
Amoxicillin–clavulanate	Amoxicillin–clavulanate — 875 mg every 12 hr†
Intravenous regimens for inpatients	
Metronidazole and a quinolone	Metronidazole — 500 mg every 6 to 8 hr
	Quinolone (e.g., ciprofloxacin — 400 mg every 12 hr)†
Metronidazole and a third-generation cephalosporin	Metronidazole — 500 mg every 6 to 8 hr
	Third-generation cephalosporin (e.g., ceftriaxone — 1–2 g every 24 hr)
Beta-lactam with a beta-lactamase inhibitor	Beta-lactam with a beta-lactamase inhibitor (e.g., ampicillin–sulbactam — 3 g every 6 hr)†

* All doses are for adults. This list is not exhaustive.

† Dose adjustment may be needed, depending on the presence and degree of renal failure.

and percutaneous or operative intervention may be required. Surgical consultation is indicated when the disease does not respond to medical management or there are repeated attacks; when there is abscess or fistula formation, obstruction, or free perforation²⁰; or when there is uncertainty regarding the diagnosis.

PERCUTANEOUS DRAINAGE

For patients in whom diverticulitis is complicated by peridiverticular abscess formation, the size of the abscess is an important determinant of the need for percutaneous drainage. Many patients who have small pericolic abscesses (4 cm or less in diameter) without peritonitis (Hinchey stage 1) can be treated conservatively with bowel rest and broad-spectrum antibiotics.²¹ For patients with peridiverticular abscesses that are larger than 4 cm in diameter^{22,23} (Hinchey stage 2), observational studies indicate that CT-guided percutaneous drainage can be beneficial. This procedure typically eliminates or reduces the size of the abscess,^{21,24,25} with a reduction in pain, resolution of leukocytosis, and defervescence usually seen within several days.²⁶ Percutaneous drainage may allow for elective rather than emergency surgery, increas-

ing the likelihood of a successful one-stage procedure. Patients whose abscess cavities contain gross feculent material tend to respond poorly, and early surgical intervention is usually required.

OPERATIVE INTERVENTION

Fewer than 10% of patients admitted with acute diverticulitis require surgical treatment during the same admission.⁵ The indications for and timing of surgery for diverticular disease are determined primarily by the severity of the disease, but other factors, including age and coexisting conditions, should also be considered.

The indications for emergency operative treatment include generalized peritonitis, uncontrolled sepsis, uncontained visceral perforation, the presence of a large, undrainable (inaccessible) abscess, and lack of improvement or deterioration within 3 days of medical management; these features are characteristic of Hinchey stage 3 or 4 disease. In the past, three separate sequential operations were performed in patients with these complications (Fig. 4), but this course of treatment is no longer recommended for most patients because of high associated morbidity and mortality.^{27,28} With this approach, many patients, especially those who are

elderly, never actually have their colostomies reversed because of the associated risks, including anastomotic leakage, small-bowel trauma, and incisional herniation or other iatrogenic injury, as well as the risks incurred from multiple operations.² Thus, many surgeons now prefer a one-stage approach whenever possible, although a two-stage approach may still be necessary (Fig. 5).

For patients who require an emergency operation, physical status and the degree of preoperative organ dysfunction are clinically significant predictors of the outcome. Preoperative hypotension, renal failure, diabetes, malnutrition, immune deficiency, and ascites are all associated with reduced odds of survival.^{29,30}

The decision whether to perform a proximal diverting procedure is based on the surgeon's assessment of the risks of anastomotic breakdown and other complications. Other factors that are considered include the patient's nutritional status, the quality of the tissues, the amount of bowel contamination, the extent of blood loss, and the intraoperative stability of the patient's condition.³¹

Reported outcomes after one- or two-stage operations for diverticulitis on the left side with peritonitis vary considerably. Increasingly, it appears that resection and primary anastomosis can be safely undertaken in selected patients — even those who have phlegmons, abscess formation with localized peritonitis, diffuse purulent peritonitis, obstruction, or fistula formation.³¹⁻³³ Although data are not available from randomized trials, observational studies that include matched patients suggest similar overall mortality rates and lower risks of wound infection and postoperative abscess formation with a one-stage approach.³⁴ This therapy is also less costly.

Complications of chronic diverticulitis, including fistulas, strictures or stenoses, and most cases of colonic obstruction, are also treated surgically. Some patients may require surgical intervention when they first present, but in most cases, the condition can be managed electively and with a one-stage operation.³⁵

LAPAROSCOPIC PROCEDURES

Most colon resections are still being performed as open procedures in the United States because laparoscopic procedures are technically challenging and tend to take longer and because relatively few

surgeons have been trained during residency or fellowship to perform them.

Data from randomized, controlled trials of open versus laparoscopic colectomy are not yet available. However, observational data suggest that as compared with patients undergoing open resections, patients who undergo laparoscopic resections tend to have shorter hospital stays, less pain in the immediate postoperative period, a reduced overall risk of complications (including pulmonary complications such as atelectasis), and fewer complications at the surgical site.³⁶

Indications for laparoscopic colectomy remain uncertain, and data on outcomes are limited. More than 90% of patients in a recent small case series underwent successful laparoscopic colectomy.³⁷ Many surgeons are now advocating laparoscopic resection for patients with stage 1 or stage 2 disease, but this approach is less well accepted for stages 3 and 4.³⁸ Laparoscopic colectomy is likely to become the standard surgical approach for uncomplicated diverticulitis as more surgeons are trained in the technique.

AREAS OF UNCERTAINTY

Randomized trials are needed to determine optimal management for acute diverticulitis, including direct comparisons of elective colectomy with medical therapy for initial or subsequent management of diverticulitis, comparisons of different open surgical procedures (one stage vs. two stages), and comparisons of open surgical procedures with laparoscopic approaches. A trial comparing open and laparoscopic surgery for diverticulitis is ongoing, but results are not expected for several years.³⁹

A major area of uncertainty is the determination of when colectomy is warranted to prevent recurrent disease and complications. Retrospective cohort studies suggest that the overall rate of recurrence is approximately 10 to 30% within a decade after a first documented attack and that the majority of patients who have a single episode of diverticulitis will not have another. In one report involving an average follow-up of 9 years with 2551 patients whose initial episode of diverticulitis was treated successfully without surgery, only 13% had recurrent attacks and only 7% required colectomy.⁴⁰ These observations imply that routine

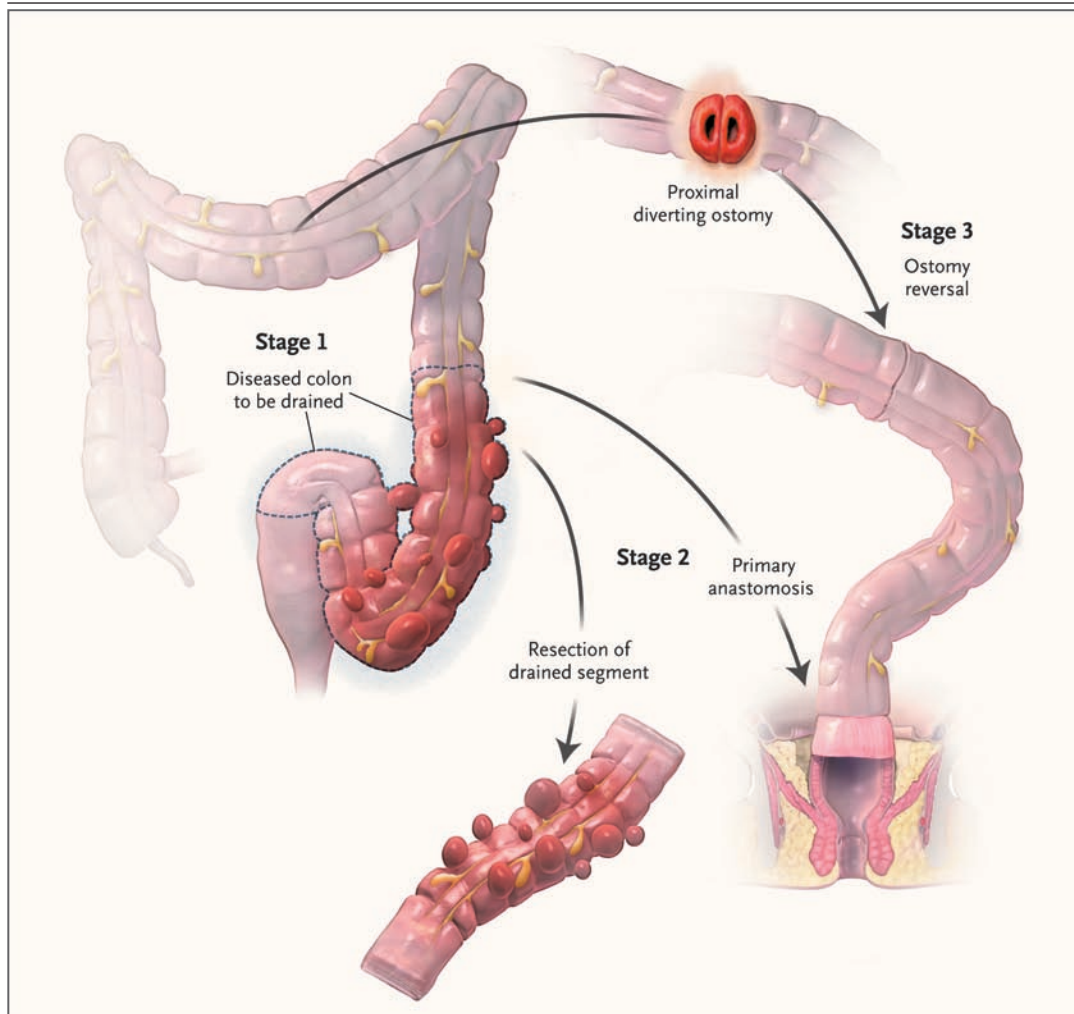


Figure 4. Three-Stage Operative Approach to Diverticulitis.

During the first operation, the diseased colonic segment is drained, and a diverting ostomy (usually a transverse colostomy) is created proximally. This first stage allows for fecal diversion and drainage of infection. During the second operation, the diseased colon is resected, and a primary anastomosis of the colonic segments is performed. The ostomy is reversed during the third and final operation to reestablish bowel continuity. The three-stage procedure is rarely performed and should be considered only in critical situations in which resection cannot be performed safely.

elective colectomy is probably unwarranted if the disease is successfully managed on initial presentation and that surgical treatment should be limited to patients whose symptoms persist despite conservative therapy.⁴¹ Thus, continued observation may be appropriate for most patients who have repeated attacks of uncomplicated diverticulitis, especially those with coexisting conditions that may complicate surgical intervention.

The presence of a diverticular abscess on admission (even if successfully drained) may indi-

cate an increased risk of recurrence.¹⁸ Some, but not all, retrospective studies suggest that the number of recurrences is associated with the chance that emergency surgery will be required at some point in the future.⁴² The likelihood that an operation will be required urgently is increased by a factor of at least two with each subsequent hospitalization for diverticulitis. In addition, patients younger than 50 years of age and those with multiple coexisting conditions, including obesity,⁴³ are more likely to have a recurrence and to require

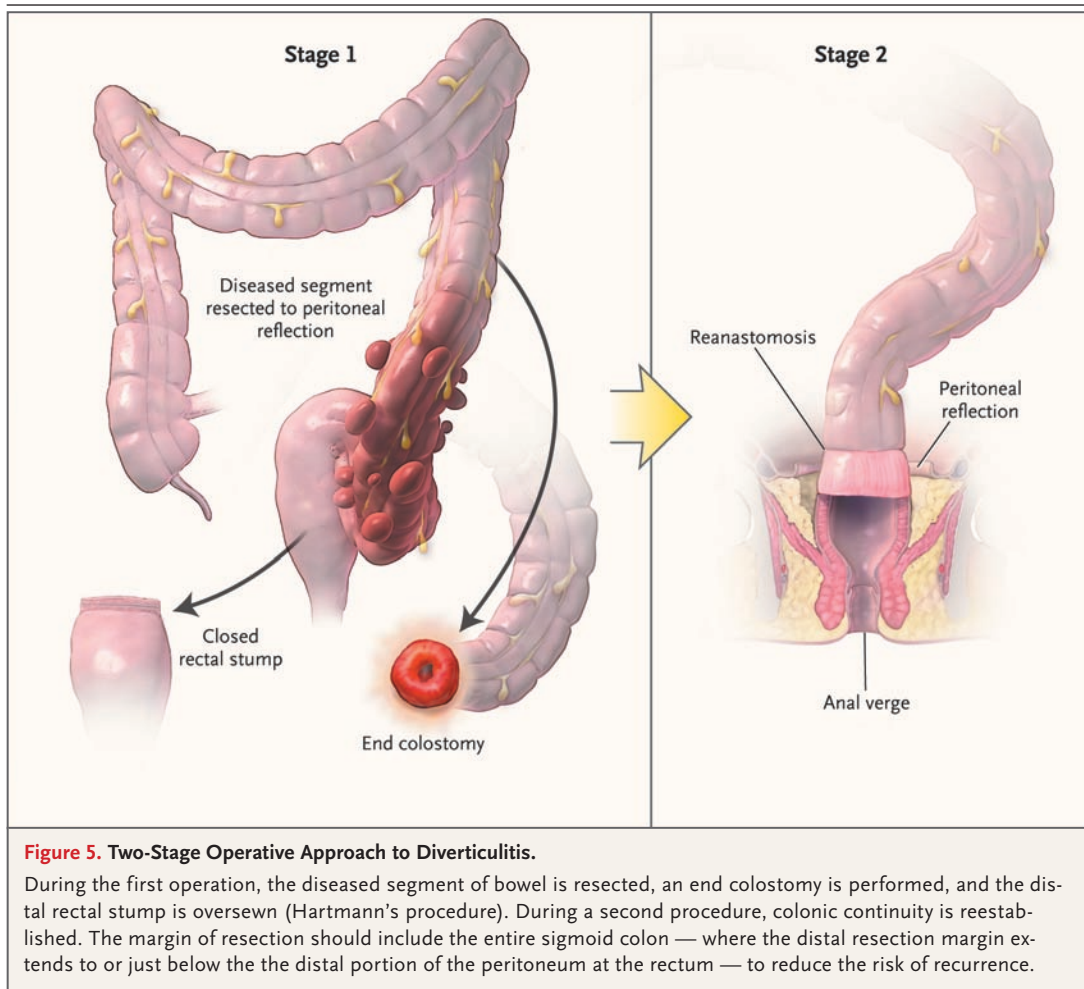


Figure 5. Two-Stage Operative Approach to Diverticulitis.

During the first operation, the diseased segment of bowel is resected, an end colostomy is performed, and the distal rectal stump is oversewn (Hartmann's procedure). During a second procedure, colonic continuity is reestablished. The margin of resection should include the entire sigmoid colon — where the distal resection margin extends to or just below the the distal portion of the peritoneum at the rectum — to reduce the risk of recurrence.

intervention.^{38,44} A recent retrospective study suggests that patients with two or more episodes of uncomplicated diverticulitis are not at increased risk for poor outcomes if complications do not develop.⁴⁵

In patients with diverticulosis, a fiber-rich diet, with or without long-term suppressive therapy with oral antibiotics, may be recommended to reduce intracolonic pressure and reduce the risk of recurrence. Epidemiologic data and the results of a small, randomized, controlled trial involving 18 patients suggest that a high-fiber diet is beneficial,⁴⁶ but conclusive data are lacking and practice standards vary widely.⁴⁷

GUIDELINES

The American Society of Colon and Rectal Surgeons has published practice guidelines⁴⁸; rec-

ommendations in this article are generally consistent with those guidelines. According to the Surgical Infection Society, treatment with intravenous antibiotics for 5 to 7 days is as effective as longer regimens.⁴⁹

CONCLUSIONS AND RECOMMENDATIONS

The patient in the vignette is unable to hydrate himself orally and should therefore be hospitalized. He should initially receive nothing by mouth and should be treated with intravenous fluids and broad-spectrum antibiotics (e.g., ciprofloxacin and metronidazole). A CT scan of the abdomen should be obtained; on the basis of the patient's presentation, it would probably show Hinchey stage 1 or 2 disease. Prompt resolution of his signs and symptoms can be expected within several days. If the

patient has not undergone colonoscopy recently, it should be performed after the inflammatory symptoms have completely resolved. Although data from randomized trials to guide dietary recommendations after discharge are lacking, many physicians would recommend a bland, low-fiber diet during recovery. Once acute symptoms have resolved, institution of a high-residue diet would not be inappropriate, although it may be unnecessary. The patient should be counseled to seek immediate

medical attention should his symptoms recur. If they do recur, surgical consultation should be considered to help determine whether elective colectomy could minimize the risk of further recurrences or complications, but uncomplicated recurrences may also be managed medically.

Dr. Jacobs reports receiving a research and educational grant from U.S. Surgical, a division of Covidien (formerly Tyco Healthcare). No other potential conflict of interest relevant to this article was reported.

REFERENCES

- Munson KD, Hensien MA, Jacob LN, Robinson AM, Liston WA. Diverticulitis: a comprehensive follow-up. *Dis Colon Rectum* 1996;39:318-24.
- Ferzoco LB, Raptopoulos V, Silen W. Acute diverticulitis. *N Engl J Med* 1998;338:1521-6.
- Tursi A. Acute diverticulitis of the colon — current medical therapeutic management. *Expert Opin Pharmacother* 2004;5:55-9.
- Ambrosetti P, Robert JH, Witzig JA, et al. Acute left colonic diverticulitis: a prospective analysis of 226 consecutive cases. *Surgery* 1994;115:546-50.
- Stollman NH, Raskin JB. Diverticular disease of the colon. *J Clin Gastroenterol* 1999;29:241-52.
- Machicado GA, Jensen DM. Acute and chronic management of lower gastrointestinal bleeding: cost-effective approaches. *Gastroenterologist* 1997;5:189-201.
- Burkitt DP, Walker ARP, Painter NS. Dietary fiber and disease. *JAMA* 1974;229:1068-74.
- Floch MH, White JA. Management of diverticular disease is changing. *World J Gastroenterol* 2006;12:3225-8.
- Parra-Blanco A. Colonic diverticular disease: pathophysiology and clinical picture. *Digestion* 2006;73:Suppl 1:47-57.
- Stollman N, Raskin JB. Diverticular disease of the colon. *Lancet* 2004;363:631-9.
- Truelove SC. Movements of the large intestine. *Physiol Rev* 1966;46:457-512.
- Brook I, Frazier EH. Aerobic and anaerobic microbiology in intra-abdominal infections associated with diverticulitis. *J Med Microbiol* 2000;49:827-30.
- Salem TA, Molloy RG, O'Dwyer PJ. Prospective study on the management of patients with complicated diverticular disease. *Colorectal Dis* 2006;8:173-6.
- Tyau ES, Prystowsky JB, Joehl RJ, Nahrwold DL. Acute diverticulitis: a complicated problem in the immunocompromised patient. *Arch Surg* 1991;126:855-8.
- Schwesinger WH, Page CP, Gaskill HV III, et al. Operative management of diverticular emergencies: strategies and outcomes. *Arch Surg* 2000;135:558-62.
- Ambrosetti P, Grossholz M, Becker C, Terrier F, Morel P. Computed tomography in acute left colonic diverticulitis. *Br J Surg* 1997;84:532-4.
- Cho KC, Morehouse HT, Alterman DD, Thornhill BA. Sigmoid diverticulitis: diagnostic role of CT — comparison with barium enema studies. *Radiology* 1990;176:111-5.
- Kaiser AM, Jiang JK, Lake JP, et al. The management of complicated diverticulitis and the role of computed tomography. *Am J Gastroenterol* 2005;100:910-7.
- Harisinghani MG, Gervais DA, Maher MM, et al. Transgluteal approach for percutaneous drainage of deep pelvic abscesses: 154 cases. *Radiology* 2003;228:701-5.
- Salzman H, Lillie D. Diverticular disease: diagnosis and treatment. *Am Fam Physician* 2005;72:1229-34.
- Ambrosetti P, Robert J, Witzig JA, et al. Incidence, outcome, and proposed management of isolated abscesses complicating acute left-sided colonic diverticulitis: a prospective study of 140 patients. *Dis Colon Rectum* 1992;35:1072-6.
- Siewert B, Tye G, Kruskal J, et al. Impact of CT-guided drainage in the treatment of diverticular abscesses: size matters. *AJR Am J Roentgenol* 2006;186:680-6. [Erratum, *AJR Am J Roentgenol* 2007;189:512.]
- Kumar RR, Kim JT, Haukoos JS, et al. Factors affecting the successful management of intra-abdominal abscesses with antibiotics and the need for percutaneous drainage. *Dis Colon Rectum* 2006;49:183-9.
- McKee RF, Deignan RW, Krukowski ZH. Radiological investigation in acute diverticulitis. *Br J Surg* 1993;80:560-5.
- Padidar AM, Jeffrey RB Jr, Mindelzun RE, Dolph JF. Differentiating sigmoid diverticulitis from carcinoma on CT scans: mesenteric inflammation suggests diverticulitis. *AJR Am J Roentgenol* 1994;163:81-3.
- Stabile BE, Puccio E, vanSonnenberg E, Neff CC. Preoperative percutaneous drainage of diverticular abscesses. *Am J Surg* 1990;159:99-104.
- Graves HA Jr, Franklin RM, Robbins LB II, Sawyers JL. Surgical management of perforated diverticulitis of the colon. *Am Surg* 1973;39:142-7.
- Wedell J, Banzhaf G, Chaoui R, Fischer R, Reichmann J. Surgical management of complicated colonic diverticulitis. *Br J Surg* 1997;84:380-3.
- Zorcolo L, Covotta L, Carlomagno N, Bartolo DC. Safety of primary anastomosis in emergency colo-rectal surgery. *Colorectal Dis* 2003;5:262-9.
- Krukowski ZH, Matheson NA. Emergency surgery for diverticular disease complicated by generalized and fecal peritonitis: a review. *Br J Surg* 1984;71:921-7.
- Belmonte C, Klas JV, Perez JJ, et al. The Hartmann procedure: first choice or last resort in diverticular disease? *Arch Surg* 1996;131:612-5.
- Salem L, Flum DR. Primary anastomosis or Hartmann's procedure for patients with diverticular peritonitis? A systematic review. *Dis Colon Rectum* 2004;47:1953-64.
- Blair NP, Germann E. Surgical management of acute sigmoid diverticulitis. *Am J Surg* 2002;183:525-8.
- Constantinides VA, Tekkis PP, Athanasiou T, et al. Primary resection with anastomosis vs. Hartmann's procedure in nonelective surgery for acute colonic diverticulitis: a systematic review. *Dis Colon Rectum* 2006;49:966-81.
- Somasekar K, Foster ME, Haray PN. The natural history of diverticular disease: is there a role for elective colectomy? *J R Coll Surg Edinb* 2002;47:481-2, 484.
- Wexner SD, Moscovitz ID. Laparoscopic colectomy in diverticular and Crohn's disease. *Surg Clin North Am* 2000;80:1299-319.
- Berthou JC, Charbonneau P. Elective laparoscopic management of sigmoid diverticulitis: results in a series of 110 patients. *Surg Endosc* 1999;13:457-60.
- Köhler L, Sauerland S, Neugebauer E. Diagnosis and treatment of diverticular disease: results of a consensus development conference. *Surg Endosc* 1999;13:430-6.
- Klarenbeek BR, Veenhof AA, de Lange ES, et al. The Sigma-trial protocol: a pro-

- spective double-blind multi-centre comparison of laparoscopic versus open elective sigmoid resection in patients with symptomatic diverticulitis. *BMC Surg* 2007;7:16.
40. Broderick-Villa G, Burchette RJ, Collins JC, Abbas MA, Haigh PI. Hospitalization for acute diverticulitis does not mandate routine elective colectomy. *Arch Surg* 2005;140:576-81.
41. Mueller MH, Glatzle J, Kasperek MS, et al. Long-term outcome of conservative treatment in patients with diverticulitis of the sigmoid colon. *Eur J Gastroenterol Hepatol* 2005;17:649-54.
42. Biondo S, Parés D, Martí-Ragué J, Kreisler E, Fracalvieri D, Jaurrieta E. Acute colonic diverticulitis in patients under 50 years of age. *Br J Surg* 2002;89:1137-41.
43. Zaidi E, Daly B. CT and clinical features of acute diverticulitis in an urban U.S. population: rising frequency in young, obese adults. *AJR Am J Roentgenol* 2006;187:689-94.
44. Anaya DA, Flum DR. Risk of emergency colectomy and colostomy in patients with diverticular disease. *Arch Surg* 2005;140:681-5.
45. Chapman JR, Dozois EJ, Wolff BG, Gullerud RE, Larson DR. Diverticulitis: a progressive disease? Do multiple recurrences predict less favorable outcomes? *Ann Surg* 2006;243:876-83.
46. Korzenik JR. Case closed? Diverticulitis: epidemiology and fiber. *J Clin Gastroenterol* 2006;40:Suppl 3:S112-S116.
47. Schechter S, Mulvey J, Eisenstat TE. Management of uncomplicated acute diverticulitis: results of a survey. *Dis Colon Rectum* 1999;42:470-5.
48. Rafferty J, Shellito P, Hyman NH, et al. Practice parameters for sigmoid diverticulitis. *Dis Colon Rectum* 2006;49:939-44.
49. Mazuski JE, Sawyer RG, Nathens AB, et al. The Surgical Infection Society guidelines on antimicrobial therapy for intra-abdominal infections: an executive summary. *Surg Infect (Larchmt)* 2002;3:161-73

Copyright © 2007 Massachusetts Medical Society.

COLLECTIONS OF ARTICLES ON THE JOURNAL'S WEB SITE

The Journal's Web site (www.nejm.org) sorts published articles into more than 50 distinct clinical collections, which can be used as convenient entry points to clinical content. In each collection, articles are cited in reverse chronologic order, with the most recent first.