

*Current Concepts***MAGNETIC RESONANCE  
CHOLANGIOPANCREATOGRAPHY**MATTHEW A. BARISH, M.D., E. KENT YUCEL, M.D.,  
AND JOSEPH T. FERRUCCI, M.D.

**M**AGNETIC resonance cholangiopancreatography (MRCP) is a radiologic technique that produces images of the pancreaticobiliary tree that are similar in appearance to those obtained by invasive radiographic methods, such as endoscopic retrograde cholangiopancreatography (ERCP). Originally described in 1991,<sup>1</sup> MRCP takes advantage of the inherent contrast-related properties of fluid in the biliary and pancreatic ducts. Because MRCP does not require the administration of any exogenous contrast materials, it is an ideal imaging method for patients with allergies to iodine-based contrast materials or those with a general history of atopy. The interest in MRCP on the part of surgeons, gastroenterologists, and radiologists is due to its accuracy, its safety, and its availability with nearly all modern magnetic resonance scanners, as well as to the fact that it is well tolerated by patients.

Currently, the diagnostic accuracy of MRCP is considered to be equivalent to that of ERCP for a broad spectrum of benign and malignant pancreatic and biliary ductal diseases.<sup>2,9</sup> ERCP continues to have certain advantages: therapeutic maneuvers can be performed at the time of the diagnostic procedure, manometry can be performed, and the ampulla can be directly visualized. In addition, the radiographic images obtained with ERCP have higher spatial resolution. Estimating the true relative costs of the techniques is difficult. However, the reimbursement allowed by Medicare for abdominal magnetic resonance imaging (MRI) is \$584.16, and the reimbursement for a diagnostic ERCP is \$670.71.

**TECHNIQUE**

The basic principle underlying MRCP is that body fluids, such as bile and pancreatic secretions, have high signal intensity on heavily T<sub>2</sub>-weighted magnetic resonance sequences (i.e., they appear white), whereas

background tissues generate little signal (i.e., they appear dark). Structures with high fluid content, such as the spleen and kidneys, will also generate some signal on T<sub>2</sub>-weighted sequences. Since a large component of residual background signal in the abdomen arises from fat, magnetic resonance techniques that allow the selective suppression of fat can substantially reduce the background signal.

The total amount of time required for examination with current magnetic resonance equipment ranges from 10 to 30 minutes. As is the case for all MRI techniques applied to the upper abdomen, respiratory motion degrades the quality of the image. Fast imaging, in which the imaging procedure is performed during a single breath-holding session, is used to reduce motion artifact. Respiratory triggering, in which the imaging procedure is timed to coincide with the patient's breathing, can be used in patients who are unable to suspend respiration. Although the specific pulse sequence used depends on the individual magnetic resonance scanner, reproducible diagnostic images have been obtained with several variations of fast spin-echo sequences.<sup>2,4,7</sup> MRCP, which preferentially visualizes the fluid in the pancreaticobiliary tree, may be used alone or in conjunction with conventional magnetic resonance techniques for visualizing the parenchymal organs of the upper abdomen.

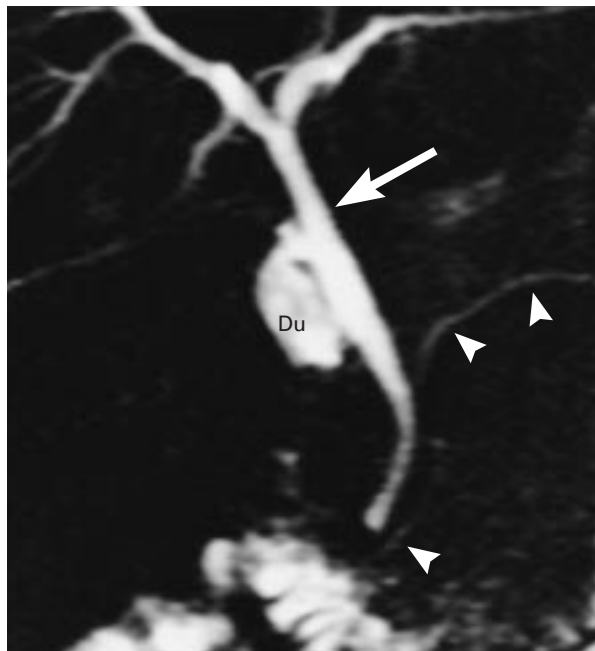
The method used to display images obtained with MRCP depends on the type of data acquired. When multislice techniques are used, the set of images forms a data set that is suitable for computer processing. The standard method of displaying the results of multislice techniques involves subjecting the data set to a maximal-intensity-projection algorithm in which only the pixel with the highest intensity along a ray perpendicular to the plane of projection is displayed. The application of this algorithm results in a two-dimensional projectional image similar in appearance to the radiographic images obtained with ERCP. Another method rapidly acquires only one thick slice of data, in which all structures containing fluid within the slice appear bright against a dark background (Fig. 1). Since only one image is obtained, processing by maximal-intensity projection is not necessary, and the single image represents the average of the data contained within the entire volume of tissue that was imaged. Both the multislice and the single-slice methods can be performed in a single breath-holding session, and the data obtained with the two methods are complementary.

**INTERPRETATION**

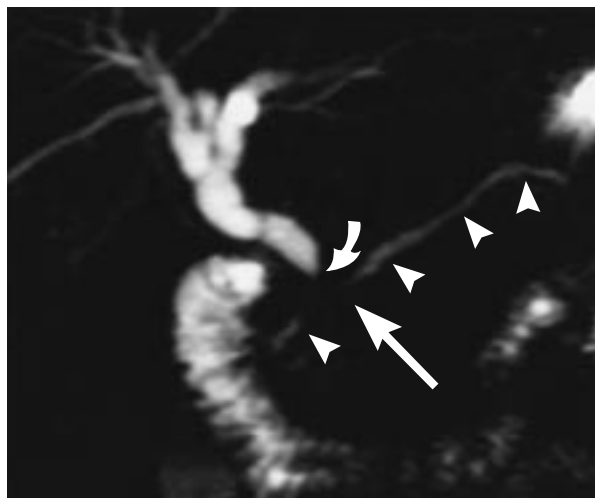
The interpretation of the images obtained with MRCP follows the basic principles of interpretation applied to ERCP. Duct caliber, anomalies, strictures, dilatation, filling defects (calculi), and extraductal collections of fluid (cysts, diverticula, and fistulas) can

From the Department of Radiology, Boston Medical Center, Boston. Address reprint requests to Dr. Barish at the Department of Radiology, Boston Medical Center, 1 Boston Medical Center Pl., Boston, MA 02118, or at mbarish@aol.com.

©1999, Massachusetts Medical Society.



**Figure 1.** Normal Results of Magnetic Resonance Cholangiopancreatography in a Patient after Cholecystectomy. Imaging was performed in two seconds with the thick, single-slice technique. The normal common bile duct (arrow) and pancreatic duct (arrowheads) are clearly visible. Du denotes duodenal bulb.



**Figure 2.** Combined Biliary-Duct Obstruction and Pancreatic-Duct Obstruction Due to a Small Mass in the Pancreatic Head. The biliary-duct obstruction is indicated by the curved arrow, and the pancreatic-duct obstruction by the straight arrow. The mass was identified on axial, contrast-enhanced,  $T_1$ -weighted images (not shown) obtained by routine MRI during the same examination. The arrowheads indicate the pancreatic duct.

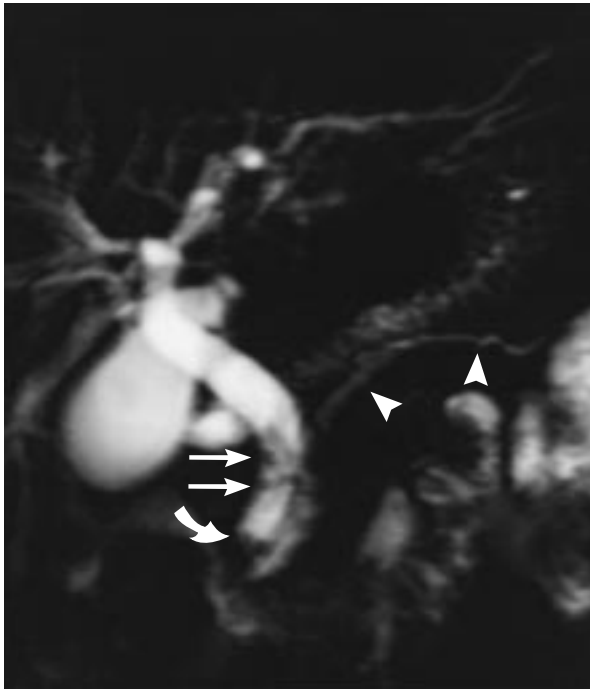
all be directly visualized by MRCP. Physiologic differences in the information provided by the two techniques are worth noting. MRCP is a passive procedure that displays the ducts in the resting state and hence more accurately displays the native caliber of the duct than ERCP. In ERCP, segments of a duct may be overdilated because of an attempt to visualize the duct upstream from a stricture, or segments may be underdilated because of the operator's fear of inducing cholangitis or pancreatitis.

In order to interpret the results of multislice MRCP, but not those of ERCP, the raw source data must be reviewed. The raw source data are the individual images, consisting of multiple coronal slices through the biliary tree. These slices may be (and usually are) assessed according to the maximal-intensity-projection algorithm previously described. Both the maximal-intensity-projection algorithm and the single-slice technique can obscure filling defects when they are surrounded by hyperintense areas of bile or pancreatic fluid. In addition, overlapping ducts, bowel, and other structures containing fluid may obscure portions of the biliary tract on the maximal-intensity-projection images but rarely cause difficulty on the individual images that make up the source data.

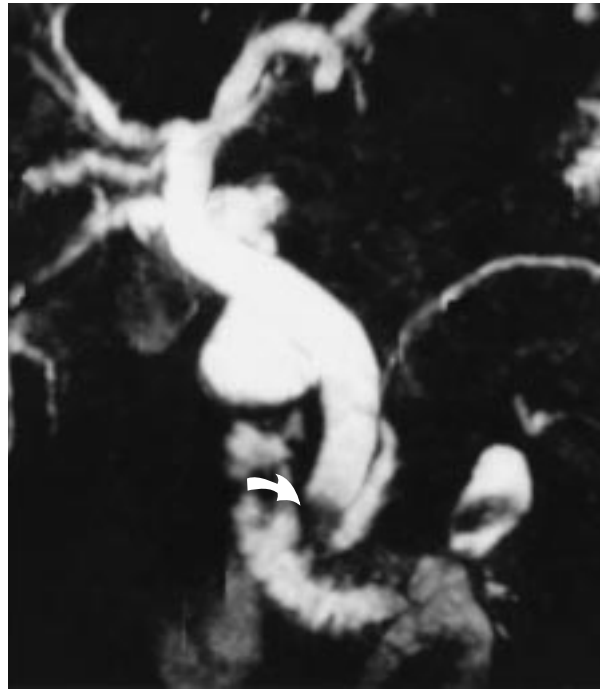#### OBSTRUCTION OF THE COMMON BILE DUCT

MRCP can visualize the normal or dilated common bile duct in 96 to 100 percent of patients.<sup>5-7</sup> Strictures typically appear as focal areas of ductal narrowing or signal void with proximal dilatation. Although the presence, site, and length of biliary strictures can be accurately identified, the cause of such strictures may be more difficult to determine on the basis of MRCP alone. Like the images obtained with conventional radiographic cholangiography, the images of areas of narrowing or stricture obtained with MRCP lack specificity, and differentiation between benign and malignant causes is based on a combination of clinical, radiographic, and pathological data. When obstructing calculi are present, the diagnosis is usually obvious on cholangiographic images obtained with either ERCP or MRCP. When obstruction of the intrapancreatic duct is a result of pancreatic adenocarcinoma (Fig. 2) or pancreatitis, the diagnosis can usually be made with the use of conventional cross-sectional MRI or computed tomography (CT).

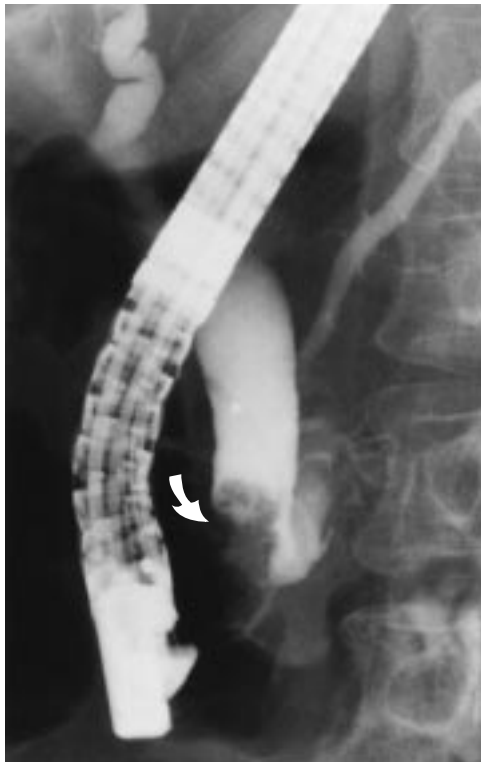
Patients with dilatation of the common bile duct who have obstruction at the ampulla are a heterogeneous group and may have either benign or malignant disease. Obstruction at the level of the ampulla can be due to ampullary carcinoma, inflammatory ampullary stenosis, dysfunction of Oddi's sphincter, or impacted stones (Fig. 3). In addition, dilatation of the duct after cholecystectomy and ampullary edema resulting from recently passed stones can have a similar cholangiographic appearance.



A



B



C

**Figure 3.** Cholangiographic Images in a Patient with Both Cholelithiasis and an Ampullary Tumor.

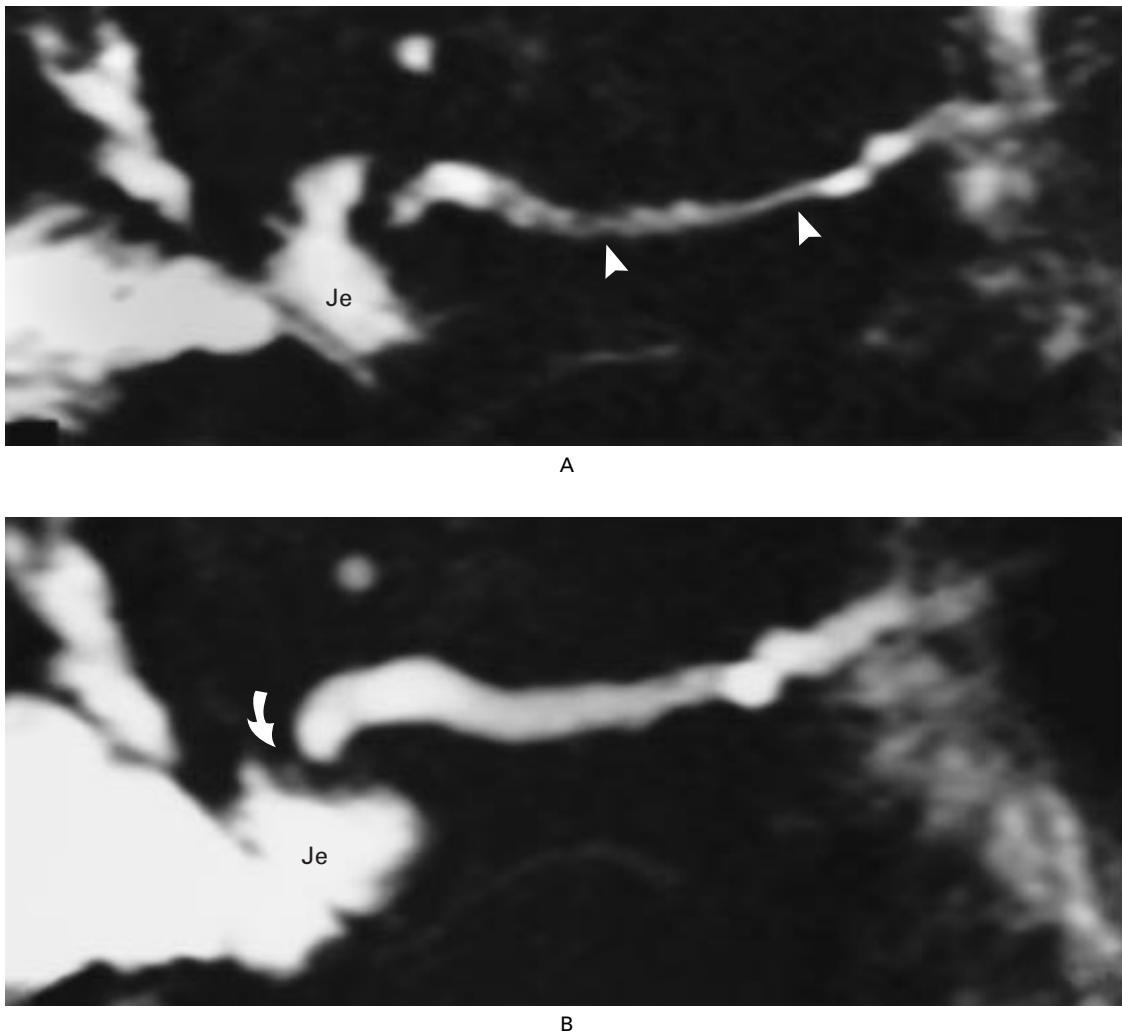
These images demonstrate the difficulties in the differential diagnosis of distal biliary obstruction. In Panel A, an image obtained with magnetic resonance cholangiopancreatography (MRCP), acquired in a single breath-holding session lasting three seconds, shows filling defects in the middle of the common bile duct; these filling defects represent small stones (straight arrows). The distal filling defect (curved arrow), representing an ampullary tumor, was originally mistaken for additional stones. The arrowheads indicate the pancreatic duct. In Panel B, an MRCP image acquired during quiet breathing (for six minutes) and processed with maximal-intensity projection provides improved visualization of the lobulated nature of the distal filling defect (curved arrow). On the basis of the results of the MRCP, the patient was referred for therapeutic endoscopic retrograde cholangiopancreatography (ERCP) for stone extraction, biopsy of the distal lesion, or both. In Panel C, an ERCP image shows more clearly the lobulated mass (arrow) that was fixed to the wall of the duct. Biopsies of the lesion revealed a benign tubular adenoma. Small mid-duct stones are obscured by the dense opacification of the duct.

ERCP has several advantages over MRCP in this heterogeneous group of patients, since it permits direct visualization of the ampulla, biopsy of lesions, manometry, or endoscopic sonography. However, when MRCP is performed in such patients, evaluation of the source data and conventional MRI may reveal a mass lesion suggestive of ampullary carcinoma.

A study of MRCP in 79 cases of biliary obstruction found that 14 of the cases had a malignant cause; in 6 cases, obstruction was due to ampullary carcinoma.<sup>5</sup> Two of the six cases were misdiagnosed as benign obstructions, and two cases of benign obstruction were thought to be ampullary cancers. This study used an early form of the technique, and results may

be more accurate with the currently available technology. In addition, the recently developed technique of dynamic, time-resolved MRCP, performed after pharmacologic stimulation with secretin, has been shown to be helpful in evaluating ampullary obstruction.<sup>10</sup>

Sequential MRCP images obtained after patients have been given secretin show prolonged and exaggerated dilatation of the pancreatic duct upstream of the ampulla (or stricture) due to obstruction of pancreatic exocrine flow (Fig. 4). Nevertheless, in a number of these cases, MRCP will not be sufficient to rule out the possibility of a mass. Endoscopic therapy thus may be indicated, and ERCP may ultimately be necessary.



**Figure 4.** Dynamic Magnetic Resonance Cholangiopancreatography (MRCP) with Intravenous Injection of Secretin in a Patient with Abdominal Pain after a Whipple Procedure.

Endoscopic retrograde cholangiopancreatography (ERCP) was not attempted because the patient had a pancreaticoenteric anastomosis. In Panel A, the pancreatic duct (arrowheads) is incompletely visualized on MRCP before the administration of secretin. In Panel B, an MRCP obtained 15 minutes after the administration of secretin shows prominent and prolonged dilatation of the pancreatic duct upstream of a stricture (arrow) at the pancreaticoenteric anastomosis. Je denotes jejunum.

### STONES OF THE COMMON BILE DUCT

Stones appear as areas of signal void within the high-signal-intensity bile on MRCP. The sensitivity of MRCP for detecting choledocholithiasis has been reported to be between 71 percent and 100 percent,<sup>2,5,6,7,11-13</sup> with a recent large study<sup>2</sup> reporting 100 percent accuracy. The sensitivity of MRCP for the detection of choledocholithiasis is superior to that of ultrasonography (20 to 65 percent)<sup>14-16</sup> and computed tomography (45 to 85 percent).<sup>17,18</sup> A meticulous review of the source images is critical in the detection of stones in the common duct that may otherwise be overlooked because they are obscured on maximal-intensity-projection reconstructions. Another potential error is the misdiagnosis of a stone as another type of intraluminal filling defect, such as an intraductal tumor, blood clot, or gas bubble (pneumobilia).<sup>19</sup>

Even though the high sensitivity and high specificity of MRCP in the diagnosis of choledocholithiasis have been established, there is no consensus on the precise role of this technique in the clinical assessment of patients with suspected choledocholithiasis. Many patients are referred for ERCP because their clinical history, their symptoms, and the results of liver-function tests indicate that there is a strong likelihood that they have stones. However, these indicators are not accurate enough to limit the use of ERCP to patients with choledocholithiasis. For example, liver-function tests performed before laparoscopic cholecystectomy lack sufficient specificity, since only 33 percent of patients with abnormal results have choledocholithiasis.<sup>20</sup> This lack of specificity results in a 40 to 70 percent incidence of negative findings with ERCP.<sup>21</sup> Hence, wider initial use of MRCP to confirm the presence of stones may be justified. In such cases, MRCP increases diagnostic certainty, thereby reserving the use of therapeutic ERCP for the patients who will benefit from it.

### FAILED OR INCOMPLETE ERCP

ERCP is a technically challenging procedure, with failure rates of 3 to 10 percent.<sup>22-24</sup> Although many failures are due to the inexperience of the operator, several anatomical factors, such as periampullary diverticula and duodenal stenosis,<sup>23,24</sup> may be responsible for difficulties in cannulation of the common bile duct. When the duct is not cannulated with conventional ERCP, precut papillotomy with a needle knife is often required, in which the needle knife is used to incise the papilla before cannulation. The incidence and severity of complications after precut papillotomy are much higher than after conventional diagnostic ERCP. The reported rate of pancreatitis and other complications after the needle-knife procedure (6 to 15 percent)<sup>22,25</sup> is higher than the rate after conventional diagnostic ERCP (1 to 5 percent).<sup>22,26,27</sup>

Other available options, such as transhepatic cho-

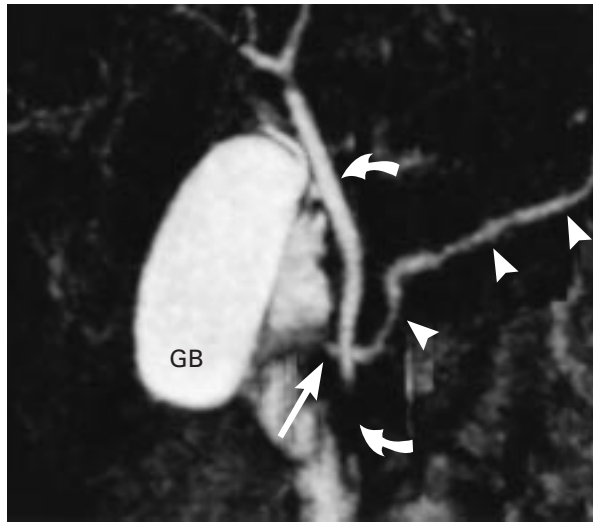
langiography, are associated with similar morbidity. MRCP is therefore indicated when the duct cannot be cannulated on ERCP, since MRCP will increase the diagnostic certainty. In a study that specifically addressed this issue, MRCP was shown to be useful for evaluating patients who had undergone unsuccessful ERCP, regardless of the reason for failure, and to be helpful in guiding patient care.<sup>28</sup>

The rate of failure of ERCP in patients who have undergone previous biliary-enteric anastomosis or a gastroenteric drainage procedure, such as a Billroth II resection, is considerably higher than the rate of failure in patients who have not undergone such surgery, with reported figures ranging from 10 percent to 48 percent.<sup>29-31</sup> In patients with a Billroth II anastomosis, the length of the afferent limb is the most important factor determining the ability to visualize the periampullary region.<sup>31</sup> In this group of patients, MRCP readily permits visualization of the site of the biliary-enteric anastomosis and shows the status of the intrahepatic ducts and the location of strictures, all of which help to determine which therapy (i.e., surgical revision, percutaneous biliary drainage, or balloon dilation of a stenotic segment) is appropriate.<sup>28,32</sup>

### THE PANCREATIC DUCT

Because the pancreatic duct is smaller than the common bile duct, it is more difficult to visualize completely. However, the normal pancreatic duct is seen on either multislice images or thick, single-slice images in more than 80 percent of patients.<sup>2,9</sup> Visualization of the pancreatic duct can be improved if imaging is performed after intravenous secretin is administered.<sup>10</sup> The administration of secretin is now frequently added to scanning protocols when the pancreatic duct is not apparent on MRCP. The use of secretin has also been reported to reduce the incidence of false positive findings of strictures of the pancreatic duct by inducing pancreatic secretions, thereby inducing distention of the duct. The increased secretion of pancreatic juices induced by the administration of secretin also causes distention of the duodenum and improves visualization of the pancreaticobiliary junction and the ampulla of Vater.

Pancreas divisum is the most common anatomical abnormality of the pancreas; it occurs when the dorsal and ventral pancreatic ducts do not fuse. On ERCP, only the ventral duct is opacified when standard cannulation of the major papilla is carried out, resulting in incomplete ductography. Moreover, the small ventral duct can be mistaken for one of the various causes of occlusion of the main duct, especially pancreatic cancer. In addition, the minor papilla may provide a functional obstruction to pancreatic secretion, resulting in elevated duct pressure and pancreatitis.<sup>33</sup> MRCP is an accurate method of diagnosing pancreas divisum, because it shows the dominant dorsal pancreatic duct continuously (Fig. 5).<sup>9,34</sup>



**Figure 5.** Normal Extrahepatic Bile Duct and Incidental Pancreas Divisum.

Magnetic resonance cholangiopancreatography is an accurate method of diagnosing pancreas divisum because it shows the dominant dorsal pancreatic duct (arrowheads) continuously from the tail to the head of the pancreas, crossing the common bile duct (curved arrows) and draining at the minor papilla (straight arrow) superiorly and separately from the common bile duct. GB denotes gallbladder.

So far, MRCP has been more useful in diagnosing and monitoring benign diseases of the pancreas, especially chronic pancreatitis, than it has been in evaluating pancreatic cancer, for which CT or conventional MRI is adequate. The use of radiologic imaging in the evaluation of chronic pancreatitis has several goals: to establish the diagnosis, to plan therapy, to detect concurrent biliary abnormalities, and to monitor for complications of the disease. Abnormal features in the pancreatic duct that can be visualized on MRCP include dilatation, narrowing or strictures, pseudocysts, and ductal filling defects representing calculi, mucinous plugs, or debris.<sup>8-10</sup> The physiologic sequelae of chronic pancreatitis, such as loss of distensibility of the duct as well as decreased exocrine function, have also been demonstrated by MRCP after stimulation with secretin.<sup>10</sup> However, MRCP is relatively insensitive to the early structural manifestations of the disease, which may include only subtle side-branch abnormalities. In addition, like ERCP, MRCP is a poor means of distinguishing benign strictures of the pancreatic ducts from those that are malignant. The inclusion of conventional MRI may improve specificity by allowing visualization of extrapancreatic structures, including liver metastases. Once the diagnosis of pancreatitis has been made, MRCP can be used to identify the most appropriate therapeutic approach — endoscopy, surgery, or continued medical management.<sup>9,28</sup>

## OTHER CONDITIONS

The use of MRCP in the evaluation of other diseases of the pancreatic and biliary tract has been less well studied. Researchers have shown that MRCP is useful in the evaluation of sclerosing cholangitis,<sup>35,36</sup> cystic neoplasm of the pancreas,<sup>37,38</sup> biliary cystic disease (such as choledochal cysts and choledochoceles),<sup>4,39</sup> and pancreatic trauma.<sup>4</sup> In addition, the technique has been used successfully in children.<sup>39,40</sup>

## LIMITATIONS

The main limitations of MRCP are the lack of availability of magnetic resonance equipment, the fact that the procedure can cause claustrophobia, and (as compared with conventional radiographic cholangiography) the inferior spatial resolution of the images. Initial difficulties relating to metallic-clip artifacts, respiratory motion, the length of the procedure, and the lack of physiologic information have largely been overcome.

## CONCLUSIONS

MRCP has become a competitive replacement for invasive imaging techniques, such as ERCP, in a wide variety of pancreatic and biliary applications. The lower cost, absence of ionizing radiation, and greater safety for patients make MRCP an attractive diagnostic method. The main role of MRCP should be to reserve the use of invasive techniques for patients in whom a therapeutic procedure is necessary.

## REFERENCES

1. Wallner BK, Schumacher KA, Weidenmaier W, Friedrich JM. Dilated biliary tract: evaluation with MR cholangiography with a T2-weighted contrast-enhanced fast sequence. *Radiology* 1991;181:805-8.
2. Fulcher AS, Turner MA, Capps GW, Zfass AM, Baker KM. Half-Fourier RARE MR cholangiopancreatography: experience in 300 subjects. *Radiology* 1998;207:21-32.
3. Lee MG, Lee HJ, Kim MH, et al. Extrahepatic biliary diseases: 3D MR cholangiopancreatography compared with endoscopic retrograde cholangiopancreatography. *Radiology* 1997;202:663-9.
4. Barish MA, Yucel EK, Soto JA, Chuttani R, Ferrucci JT. MR cholangiopancreatography: efficacy of three-dimensional turbo spin-echo technique. *AJR Am J Roentgenol* 1995;165:295-300.
5. Guibaud L, Bret PM, Reinhold C, Atri M, Barkun AN. Bile duct obstruction and choledocholithiasis: diagnosis with MR cholangiography. *Radiology* 1995;197:109-15.
6. Soto JA, Barish MA, Yucel EK, Siegenberg D, Ferrucci JT, Chuttani R. Magnetic resonance cholangiography: comparison to endoscopic retrograde cholangiopancreatography. *Gastroenterology* 1996;110:589-97.
7. Macaulay SE, Schulte SJ, Sekijima JH, et al. Evaluation of a non-breath-hold MR cholangiography technique. *Radiology* 1995;196:227-32.
8. Takehara Y, Ichijo K, Tooyama N, et al. Breath-hold MR cholangiopancreatography with a long-echo-train fast spin-echo sequence and a surface coil in chronic pancreatitis. *Radiology* 1994;192:73-8.
9. Soto JA, Barish MA, Yucel EK, et al. Pancreatic duct: MR cholangiopancreatography with a three-dimensional fast spin-echo technique. *Radiology* 1995;196:459-64.
10. Matos C, Metens T, Deviere J, et al. Pancreatic duct: morphologic and functional evaluation with dynamic MR pancreatography after secretin stimulation. *Radiology* 1997;203:435-41.
11. Guibaud L, Bret PM, Reinhold C, Atri M, Barkun AN. Diagnosis of choledocholithiasis: value of MR cholangiography. *AJR Am J Roentgenol* 1994;163:847-50.
12. Chan Y-L, Chan ACW, Lam WWM, et al. Choledocholithiasis: comparison of MR cholangiography and endoscopic retrograde cholangiopancreatography. *Radiology* 1996;200:85-9.

13. Regan F, Fradin J, Khazan R, Bohlman M, Magnuson T. Choledocholithiasis: evaluation with MR cholangiography. *AJR Am J Roentgenol* 1996;167:1441-5.
14. Gross BH, Harter LP, Gore RM, et al. Ultrasonic evaluation of common bile duct stones: prospective comparison with endoscopic retrograde cholangiopancreatography. *Radiology* 1983;146:471-4.
15. Cronan JJ, Mueller PR, Simeone JF, et al. Prospective diagnosis of choledocholithiasis. *Radiology* 1983;146:467-9.
16. Laing FC, Jeffrey RB Jr. Choledocholithiasis and cystic duct obstruction: difficult ultrasonographic diagnosis. *Radiology* 1983;146:475-9.
17. Jeffrey RB, Federle MP, Laing FC, Wall S, Rego J, Moss AA. Computed tomography of choledocholithiasis. *AJR Am J Roentgenol* 1983;140:1179-83.
18. Baron RL, Stanley RJ, Lee JKT, Koehler RE, Levitt RG. Computed tomographic features of biliary obstruction. *AJR Am J Roentgenol* 1983;140:1173-8.
19. David V, Reinhold C, Hochman M, et al. Pitfalls in the interpretation of MR cholangiopancreatography. *AJR Am J Roentgenol* 1998;170:1055-9.
20. Cranley B, Logan H. Exploration of the common bile duct — the relevance of the clinical picture and the importance of preoperative cholangiography. *Br J Surg* 1989;67:869-72.
21. Philips EH. Controversies in the management of common duct calculi. *Surg Clin North Am* 1994;74:931-48.
22. Bilbao MK, Dotter CT, Lee TG, Katon RM. Complications of endoscopic retrograde cholangiopancreatography (ERCP): a study of 10,000 cases. *Gastroenterology* 1976;70:314-20.
23. Silvis SE, Ansel HJ. Endoscopic retrograde cholangiography: application in biliary tract disease. In: Berk JE, ed. *Bockus gastroenterology*. 4th ed. Vol. 6. Philadelphia: W.B. Saunders, 1985:3569-80.
24. Rieger R, Wayand W. Yield of prospective, noninvasive evaluation of the common bile duct combined with selective ERCP/sphincterotomy in 1390 consecutive laparoscopic cholecystectomy patients. *Gastrointest Endosc* 1995;42:6-12.
25. Dowsett JF, Polydorou AA, Vaira D, et al. Needle knife papillotomy: how safe and how effective? *Gut* 1990;31:905-8.
26. Hamilton I, Lintott DJ, Rothwell J, Axon ATR. Acute pancreatitis following endoscopic retrograde cholangiopancreatography. *Clin Radiol* 1983;34:543-6.
27. Thoeni RF, Fell SC, Goldberg HI. CT detection of asymptomatic pancreatitis following ERCP. *Gastrointest Radiol* 1990;15:291-5.
28. Soto JA, Yucel EK, Barish MA, Chuttani R, Ferrucci JT. MR cholangiopancreatography after unsuccessful or incomplete ERCP. *Radiology* 1996;199:91-8.
29. Forbes A, Cotton PB. ERCP and sphincterotomy after Billroth II gastrectomy. *Gut* 1984;25:971-4.
30. Osnes M, Rosseland AR, Aabakken L. Endoscopic retrograde cholangiography and endoscopic papillotomy in patients with a previous Billroth-II resection. *Gut* 1986;27:1193-8.
31. Cunningham JT. Endoscopic papillotomy and stent insertion: B-II technique and limitations. In: Barkin JS, O'Phelan CA, eds. *Advanced therapeutic endoscopy*. New York: Raven Press, 1990:193-200.
32. Pavone P, Laghi A, Catalano C, Brogna L, Messina A, Passariello R. Three-dimensional MR cholangiography: a unique diagnostic procedure for evaluation of bile ducts in patients with biliary-enteric anastomosis. *Radiology* 1995;197:Suppl:312. abstract.
33. Lehman GA, Sherman S. Pancreas divisum: diagnosis, clinical significance, and management alternatives. *Gastrointest Endosc Clin North Am* 1995;5:145-70.
34. Bret PM, Reinhold C, Taourel P, Guibaud L, Atri M, Barkun AN. Pancreas divisum: evaluation with MR cholangiopancreatography. *Radiology* 1996;199:99-103.
35. Ernst O, Asselah T, Sergent G, et al. MR cholangiography in primary sclerosing cholangitis. *AJR Am J Roentgenol* 1998;171:1027-30.
36. Ernst O, Asselah T, Talbodec N, Sergent G. MR cholangiopancreatography: a promising new tool for diagnosing primary sclerosing cholangitis. *AJR Am J Roentgenol* 1997;168:1115-6.
37. Onaya H, Itai Y, Niitsu M, Chiba T, Michishita N, Saida Y. Ductectatic mucinous cystic neoplasms of the pancreas: evaluation with MR cholangiopancreatography. *AJR Am J Roentgenol* 1998;171:171-7.
38. Koito K, Namieno T, Ichimura T, et al. Mucin-producing pancreatic tumors: comparison of MR cholangiopancreatography with endoscopic retrograde cholangiopancreatography. *Radiology* 1998;208:231-7.
39. Yamataka A, Kuwatsuru R, Shima H, et al. Initial experience with non-breath-hold magnetic resonance cholangiopancreatography: a new noninvasive technique for the diagnosis of choledochal cyst in children. *J Pediatr Surg* 1997;32:1560-2.
40. Guibaud L, Lachaud A, Touraine R, et al. MR cholangiography in neonates and infants: feasibility and preliminary applications. *AJR Am J Roentgenol* 1998;170:27-31.